

A sound solution for Trigeminal Neuralgia

Our primary preliminary experience with 15 cases treated at Sheba Medical Center

Dr Haim- Moshe Adahan, Head of the Pain Rehabilitation Unit of Sheba Medical Center

Dr Yaacov Ezra, Staff Neurology & Pain Divisions, Hadassah Hospital of Jerusalem

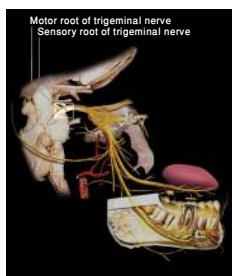
Dr Itschak Siev-Ner, Head of the Orthopedic Rehabilitation Division, Sheba Medical Center

Introduction

Trigeminal neuralgia (TN) is one of the most severe and progressive forms of chronic neuropathic pain. The latest scientific work has shown that the likely anatomic cause of the TN is a highly reversible tiny CNS lesion at the root entry zone of the trigeminal nerve measuring less than 0.5 cm³.

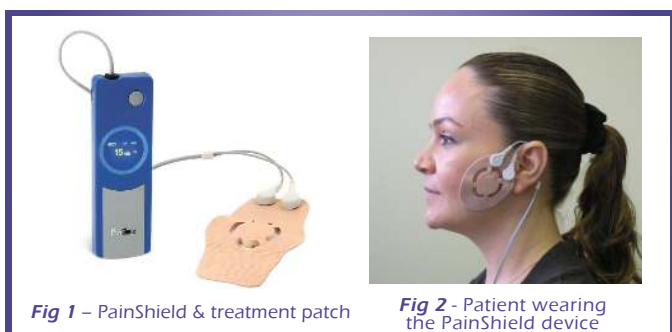The presence of a discrete, highly eloquent and highly reversible CNS lesion presents a unique opportunity to test and measure the Neuroregenerative potential of therapeutic modalities that can be effectively delivered to the site of this pathology. Neuroregeneration refers to the regrowth or repair of nervous tissues or cell.

Ultrasound delivered to injured nerves has been shown in animal studies^{i ii iii iv v} to have neuroregenerative capacities and has also been associated with improved remyelination in human carpal tunnel syndrome in 1 RCT^{vi}. Until the advent of readily clinically applicable surface acoustic ultrasound technology, there was no clinically available ultrasound device that could safely extend its therapeutic effect for a prolonged period intra-cranially where the lesion of the trigeminal nerve is located.



Methods

15 TN patients were treated with a Low Intensity, Low Frequency, Surface Acoustic Wave (LILF/SAW) device (PainShield - NanoVibronix Ltd. Neshar, Israel) [Fig 1]. Patients were instructed to use the device daily, overnight and remove it upon waking. The device was programmed to work in cycles of 30 minutes on and 30 minutes off, for a total of 8 hours of intermittent treatment. If tolerable, the patient was asked to apply the PainShield actuator so that it abuts next to a bony prominence in the painful region; such as the zygomatic arch in V2 pain [Fig 2] or the lower mandible area in V3 pain. In some cases where the allodynia did not permit wearing the patch on the painful zone, the actuator was applied on the forehead.



Results

73 % of the subjects experienced complete or near complete relief. In nearly all cases, there was a delay of 1-2 weeks before the onset of relief followed by a gradual improvement over the following 2-6 weeks. Most patients had reached a plateau in improvement after 2 months of use. Stopping the treatment led to partial recurrence in some patients. 3 out of the four MS patients suffered pain recurrence despite continued PainShield use; All 4 of our MS subjects suffered from a progressive form of MS.

References

ⁱ Low-intensity pulsed ultrasound accelerates the regeneration of the sciatic nerve after neurotomy in rats. Crisci A.R., Ferreira A.L. *Ultrasound in Med. & Biol.*, 2002; 28(10):1335-1341

ⁱⁱ The effects of low-intensity ultrasound on peripheral nerve regeneration in Poly(DL-lactic acid-co-glycolic acid) conduits seeded with Schwann cells. Chang C.-J., Hsu S.-H. *Ultrasound in Med. & Biol.*, 2004; 30(8):1079-1084

ⁱⁱⁱ Ultrasound Accelerates Functional Recovery after Peripheral Nerve Damage. Mourad P.D., Lazar D.A., Curra F.P., Mohr B.C., Andrus K.C., Avellino A.M., McNutt L.D., Crum L.A., Kliot M. *Neurosurgery*, 2001; 48(5):1136-1140

^{iv} Ultrasound therapy facilitates the recovery of the acute pressure-induced conduction block of the median nerve in rabbits. Paik N.-J., Cho S.-H., Han T.R., *Muscle Nerve*, 2002; 26: 356-361

Trigeminal Neuralgia Patients' Outcome

TN Stage	n	Descriptor	No response	Response <75%	Response >75%	Complete relief	Temporary relief and refractory recurrence
A	1	Intermittent pain crises				1	
B	1	No pain, but need for continuous meds. With problematic side effects					1
C	2	Pain crisis despite continuous meds				2	
D	11	Daily chronic pain despite continuous meds With problematic side effects	1 Moderate transient pain aggravation at site of dental implant		2	6	2
Summary	15		6.67%		13%	60%	20%

73% of patients, most with severe disabling refractory pain, got relieved of most or all of their pain

Discussion

This novel approach of delivering LILF ultrasound allows for longer and more effective treatments. The Surface Acoustic Waves, unlike traditional ultrasound, are characterized by elliptical particle movement travelling with great efficiency across bony surfaces^{vii}. When applied to a bony surface, such as the forehead, the LILF/SAW will travel and reach the entire surface of the skull and be effectively and efficiently transmitted via the CSF to the CNS structures juxtaposed against the bony structures. Hence, the root entry zone of the trigeminal nerve as well as the entire length of all its branches are exposed to LILF/SAW which also travel along the bony surface inside the cranial nerve foramina.

The recurrence of pain in some patients, may be subsequent to the progress of the demyelinating illness deeper in brain or that the disease itself progressed beyond the capacity of our treatment modality to stop it.

In addition to the hypothesized neuroregenerative effects of the LILF/SAW, it may also bring the added advantage of a wide surface Phonophoresis effect and possibly a mechanical washout of accumulated pro-algesic substances in the nerve itself as well as the facial soft tissues. This would be caused by the mechanical effect of a 2 micron unidirectional mechanical pressure wave traveling through these tissues at 90kHz. In some of the cases described in this report, the Phonophoretic effect inherent to ultrasound also became evident when PainShield treatment was combined with compounded topical medicine crèmes containing ketamine, and various anti-epileptic drugs amongst others^{viii}.

Conclusion

The results obtained in this open label series definitely point to the need to further research this treatment modality in a larger scale RCT. Further research evaluating the benefit of combining the Phonophoretic effect of the LILF/SAW with topical ketamine solutions should also be considered in light of a recent RCT confirming the benefit of topical ketamine in neuropathic pain^{ix}. This technology is able to deliver LILF/SAW to the entire outer surface of the brain and brainstem and, in some cases, to certain locations of the spinal cord by using the CSF as a bridging ultrasound conducting medium. There are no lack of potentially reversible pathologies in those anatomical locations in need of a treatment with neuroregenerative potential.

^v Low-intensity ultrasound for regeneration of injured peripheral nerve. Zhou W., Chen W., Zhou K., Wang Z. *Neural regeneration research*, 2006; 1(7)

^{vi} Ultrasound treatment for treating the carpal tunnel syndrome: randomised "sham" controlled trial. Ebenbichler G.B., Resch K.L., Nicolakis P., Wiesinger G.F., Uhl F., Ghanem A.-H., Fialka V. *BMJ*, 1998; 316:731-735

^{vii} Surface Acoustic Wave Devices for mobile and wireless communications. C.K.Campbell. Dep. of electrical eng., McMaster Un., Hamilton, Canada, 1998

^{viii} The Use of Sonophoresis in the Administration of Drugs Throughout the Skin. José Juan Escobar-Chávez, Dalia Bonilla-Martínez, Martha Angélica Villegas-González, Isabel, Marlen Rodríguez-Cruz, Clara Luisa Domínguez-Delgado *J Pharm Pharmaceut Sci* 12 (1): 88 - 115, 2009.

^{ix} Reduction of allodynia in patients with complex regional pain syndrome: A double-blind placebo-controlled trial of topical ketamine. Philip M. Finch, Lone Knudsen, Peter D. Drummond. *PAIN*, 146 (2009) 18-25