

Surface Acoustic Wave Patch Diathermy Generates Healing In Hard To Heal Wounds

Jonathan Rosenblum DPM¹, Constantine Reinus MD PhD²

¹Director, Diabetic Foot Service; Shaarei Zedek Medical Center, Jerusalem, Israel,

²Chairman, Department of Pathology; Shaarei Zedek Medical Center, Jerusalem, Israel

BACKGROUND

We set forth to study the effect of the PainShield*, a low intensity ultrasound patch based device, on the chronic wound bed in Diabetic Foot Ulcers. The PainShield generates low intensity, low frequency, surface acoustic wave energy at the tissue surface and up till an effective depth of approximately 3cm, thereby energy in the target layers of the epidermis and dermis. This has allowed us to target diabetic wounds with therapeutic ultrasound by placing the patch of the PainShield on normal skin adjacent to wounds.

PainShield used in this fashion was shown to be a safe and effective tool for wound care.

METHODS

Patients with chronic Diabetic Foot Ulcers were enrolled in an open label study of one week duration to evaluate the effects of the PainShield device on the wound bed as evaluated by histological analysis.

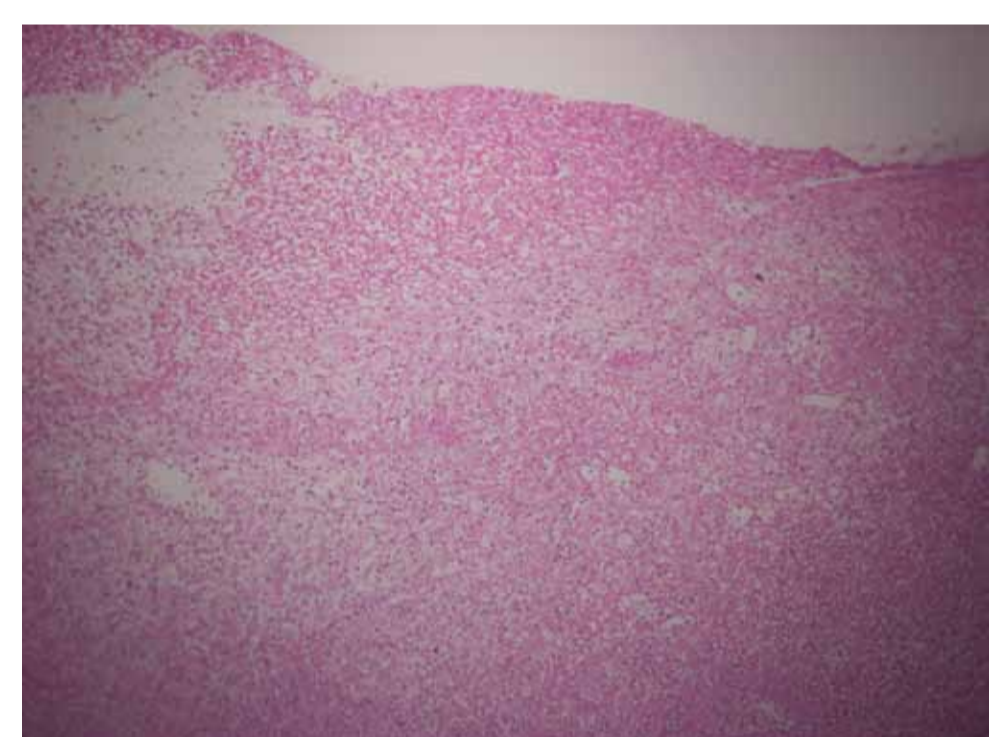
The wound beds were biopsied with a 2mm punch biopsy and the sample was evaluated in the dermatopathology lab for gross evaluation, quantification of precursors of dermal and epidermal growth including GAG's, the number of cells in mitosis as well as the amount of Collagen present.

Treatment consisted of a moist sterile dressing with saline as well as use of the PainShield Patch for 8 hours per day of cycled (half hour on, half hour off) treatment for a period of 1 week.

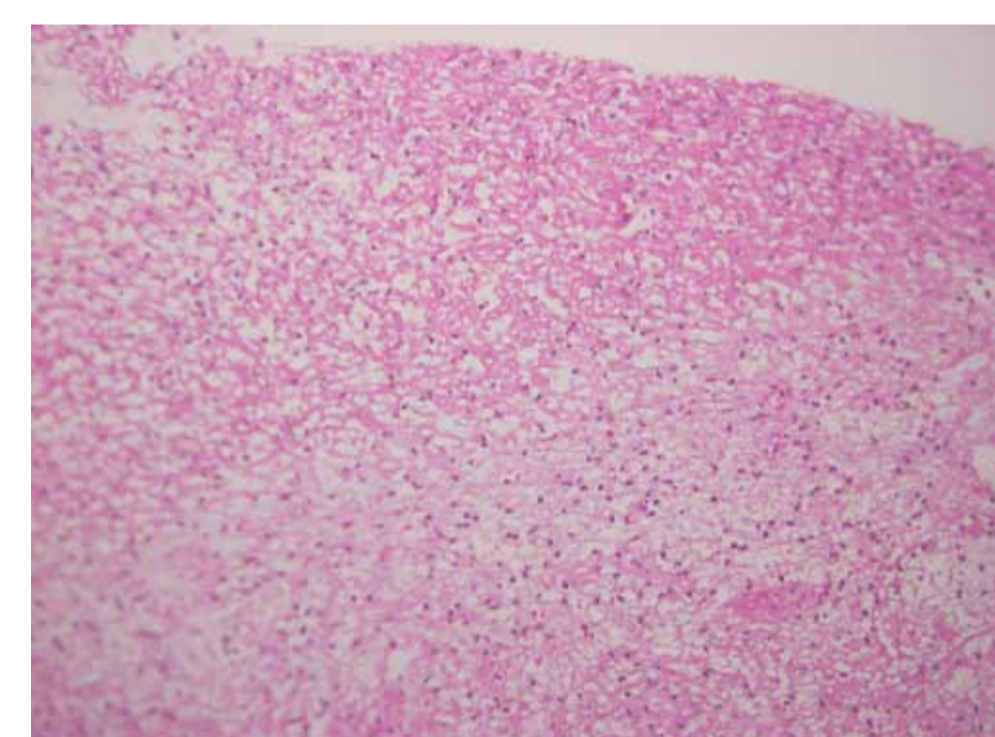
After 1 week of treatment patients were reevaluated in the same manner as before treatment and the same parameters were measured and compared.

RESULTS

H&E Staining

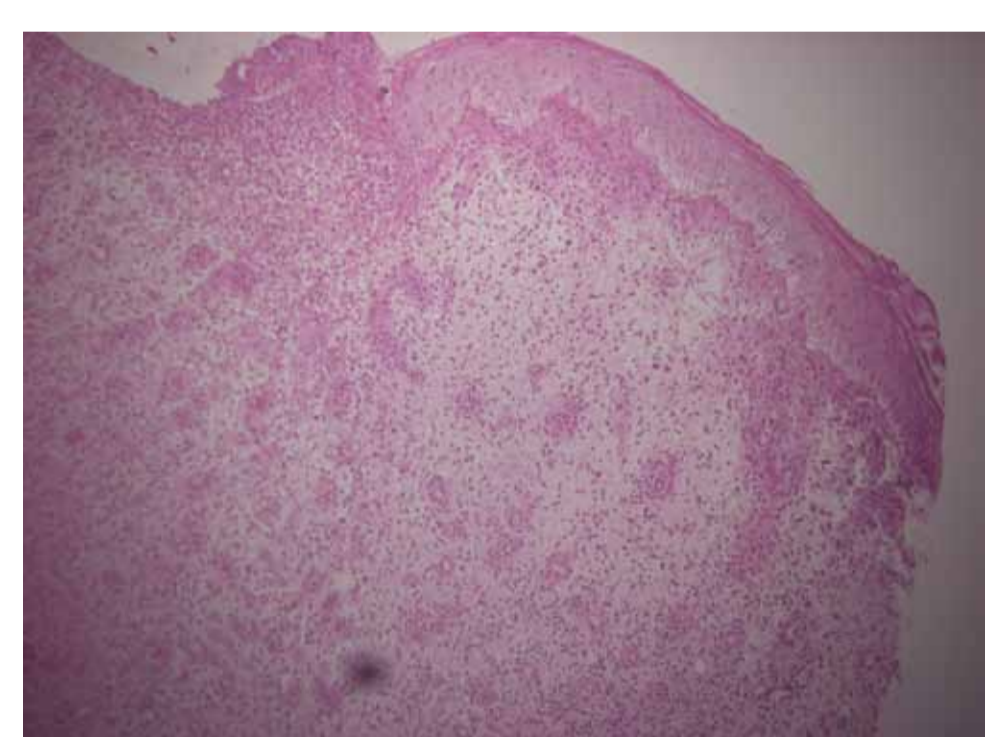


100x Magnification Pre-Treatment

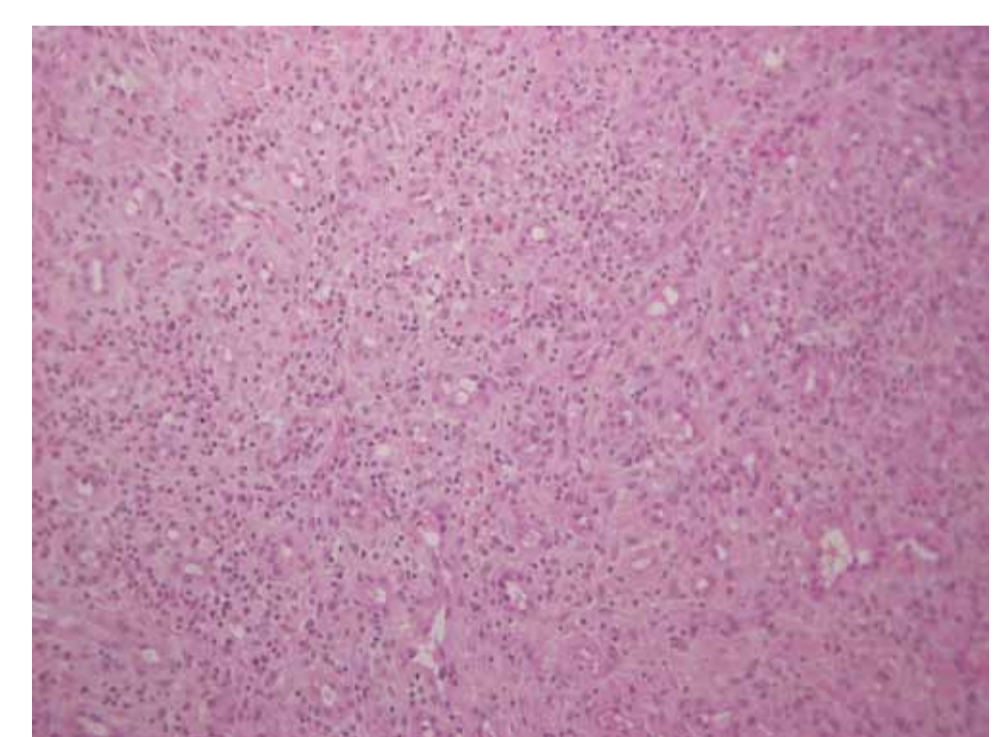


200x Magnification Pre-Treatment

Note the Layer of Fibrin, Signs of Gangrene, Acute Exudate, Necrotic Tissue and PMN's. Note the Lack of: Granulation Tissue. Vascularization, and Epithelialization.



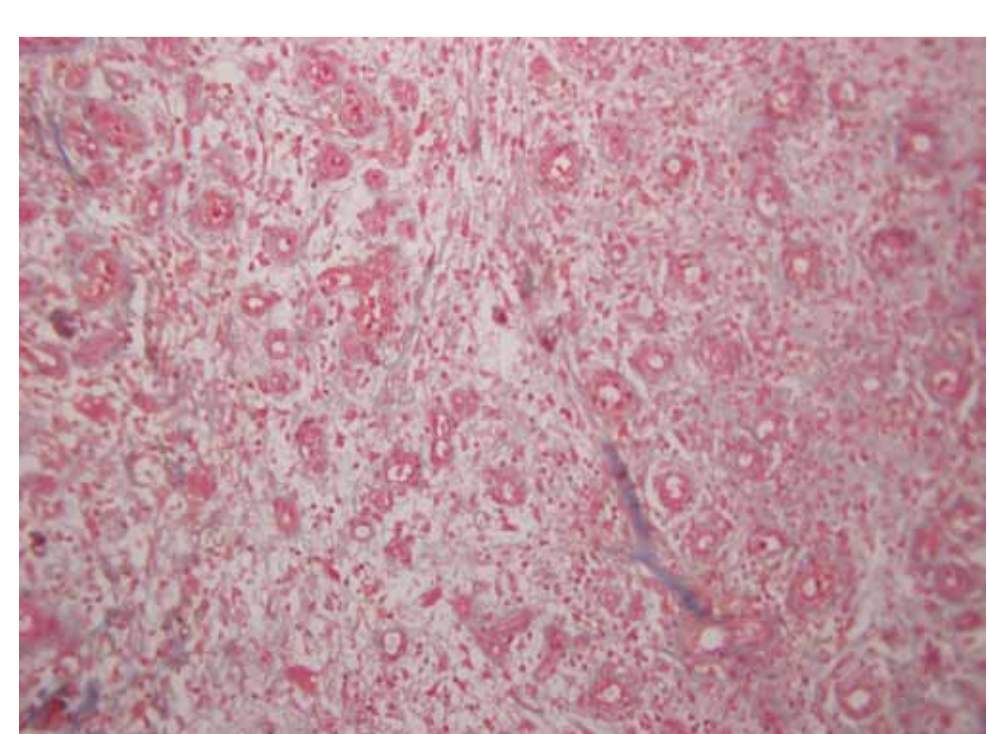
100x Magnification Post-Treatment



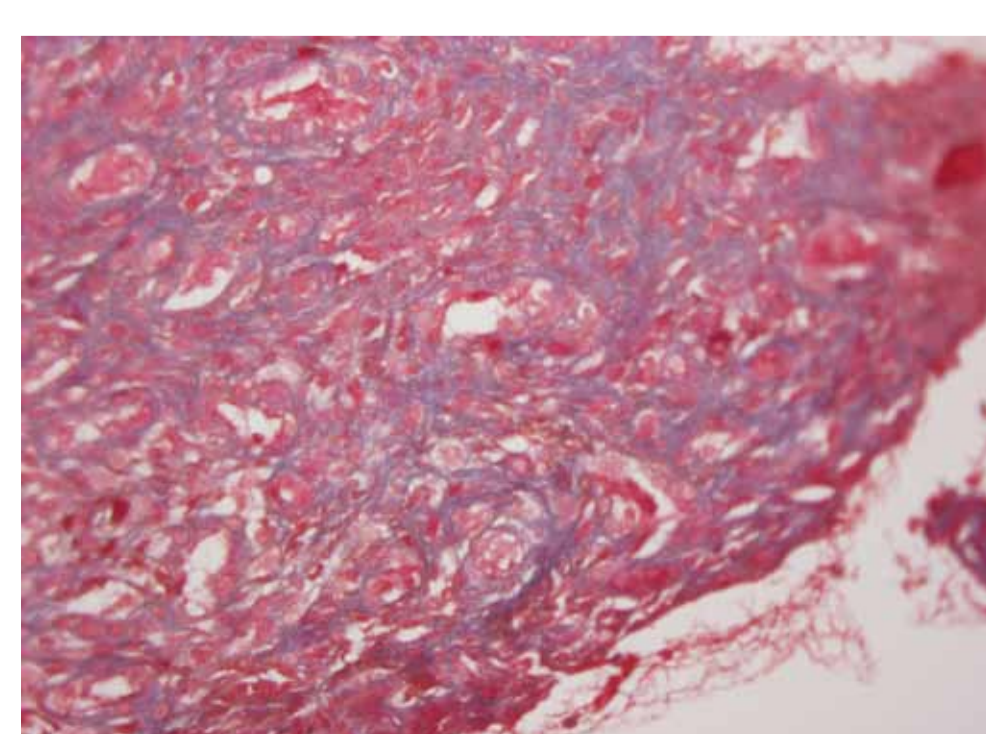
200x Magnification Post-Treatment

Note the significant decrease in Necrotic tissue, increase in Granulation Tissue, and the Early Signs of Fibrosis (an early indicator for future scarring).

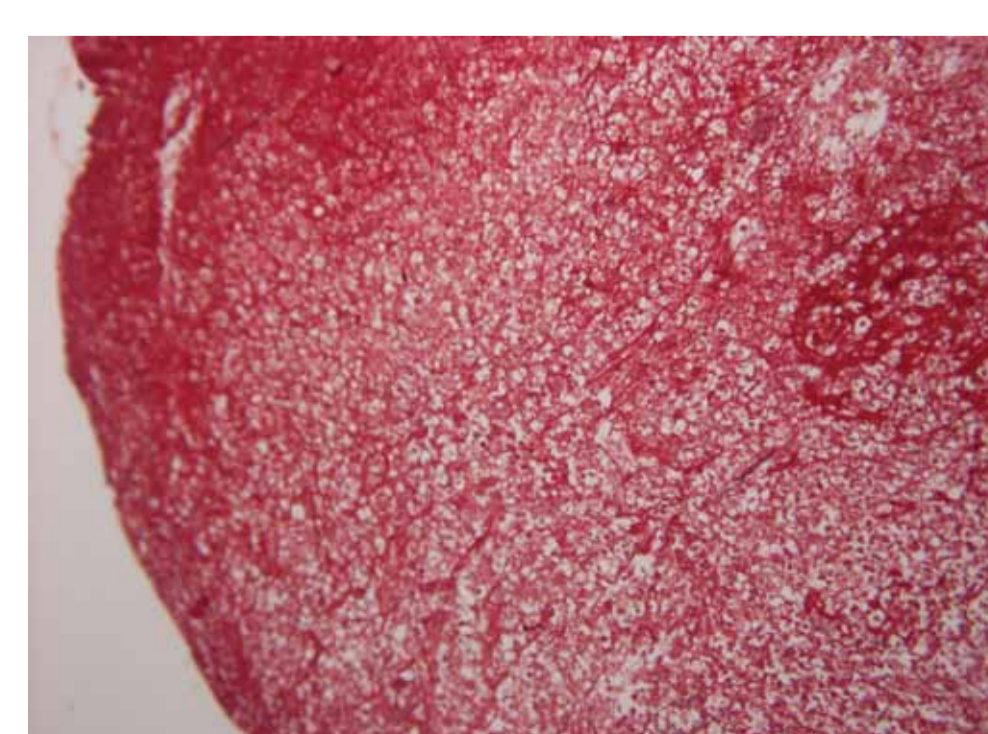
Collagen Synthesis - MTC (Masson Tri-Chrome) Staining



100x Mag Pre-Treatment



200x Mag Post-Treatment

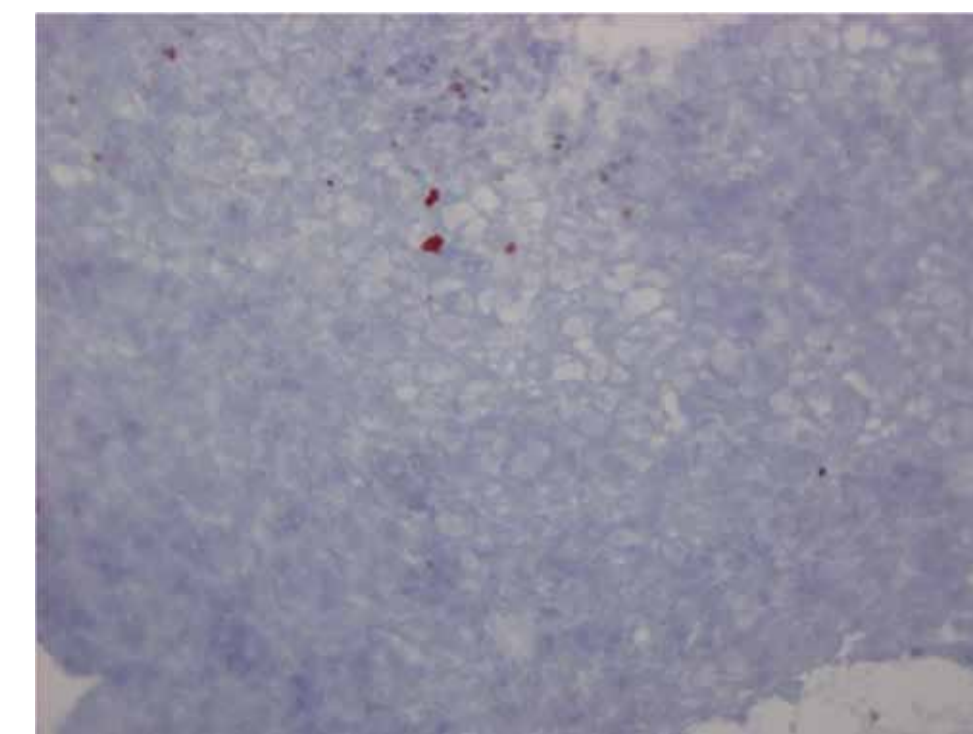


400x Mag Post-Treatment

The lack of staining signifies the lack of presence of Collagen.

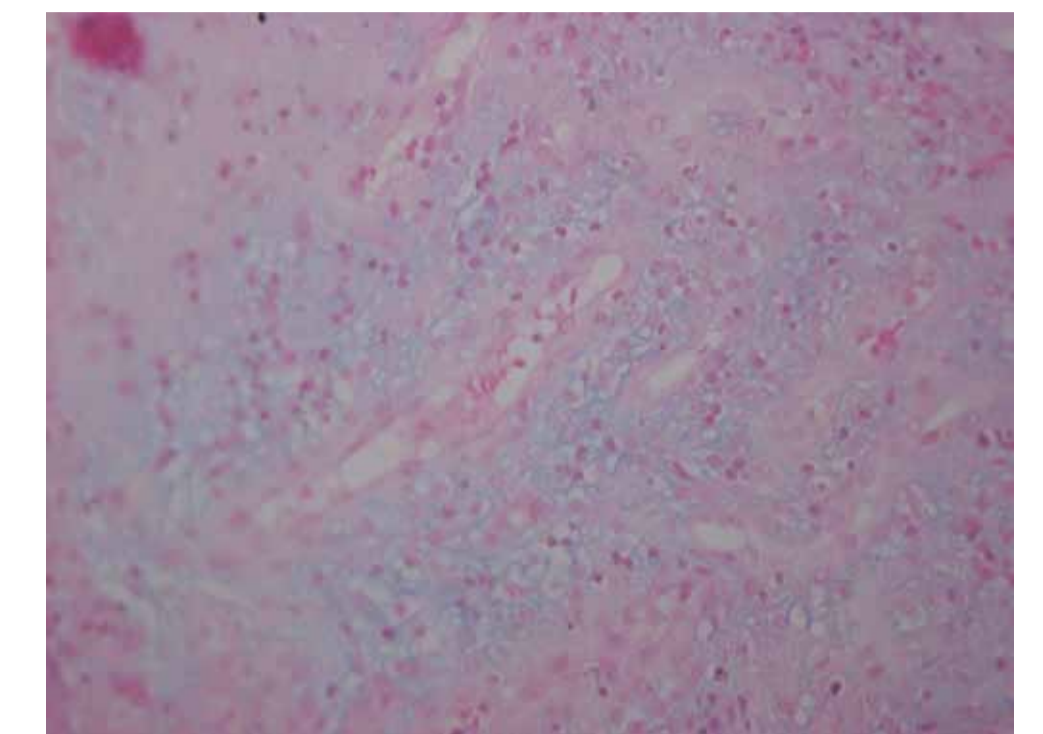
The intense blue staining and the organization of the Collagen layers signifies new Collagen production. This is significant for the regenerative stage of healing.

Glycose Amino Glyeans (GAG) Production



400x Mag of Alcian Green Staining Pre-Treatment

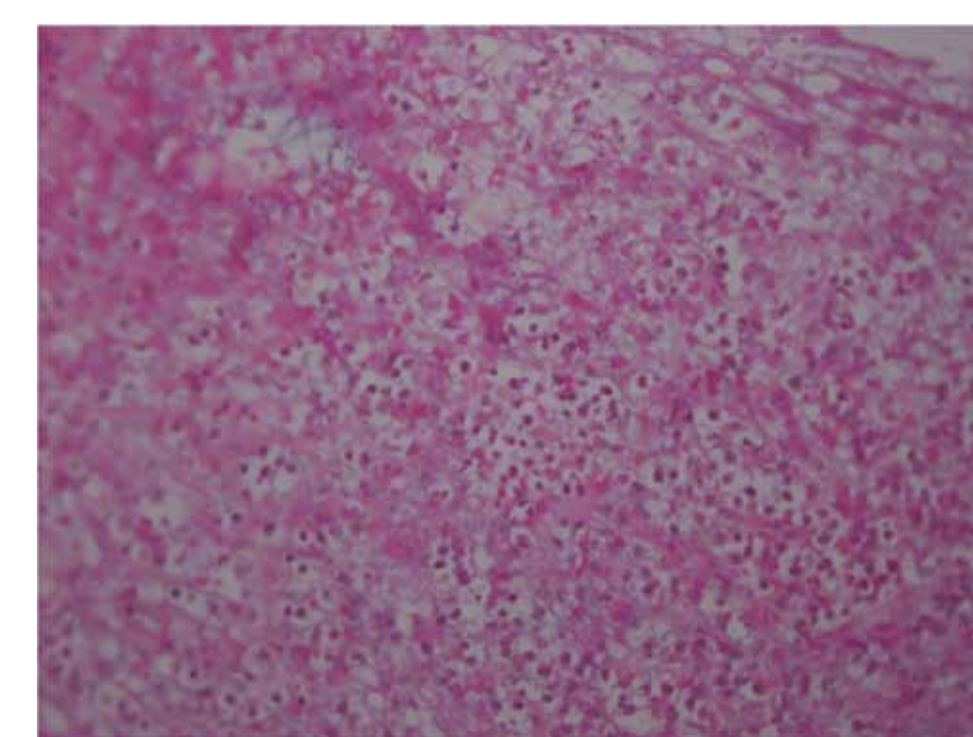
Note the complete lack of staining for GAG's.



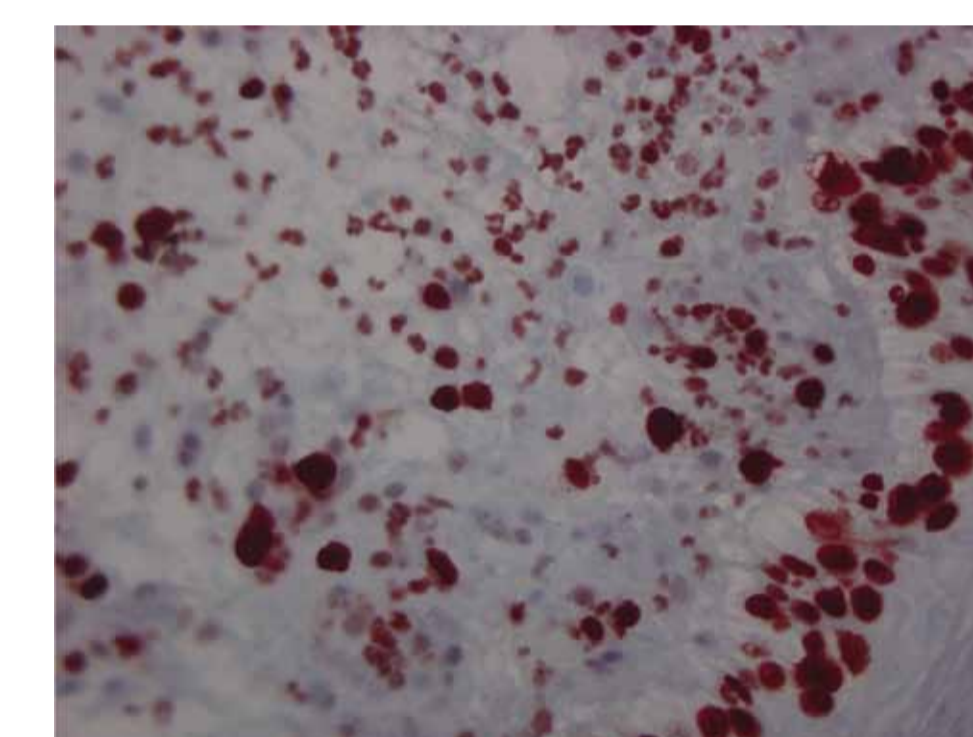
400x Mag of Alcian Green Staining Post-Treatment

Note the ++ staining for GAG's and the diffuse distribution of GAG's in the tissue.

Cells in Mitosis Ki67 Staining

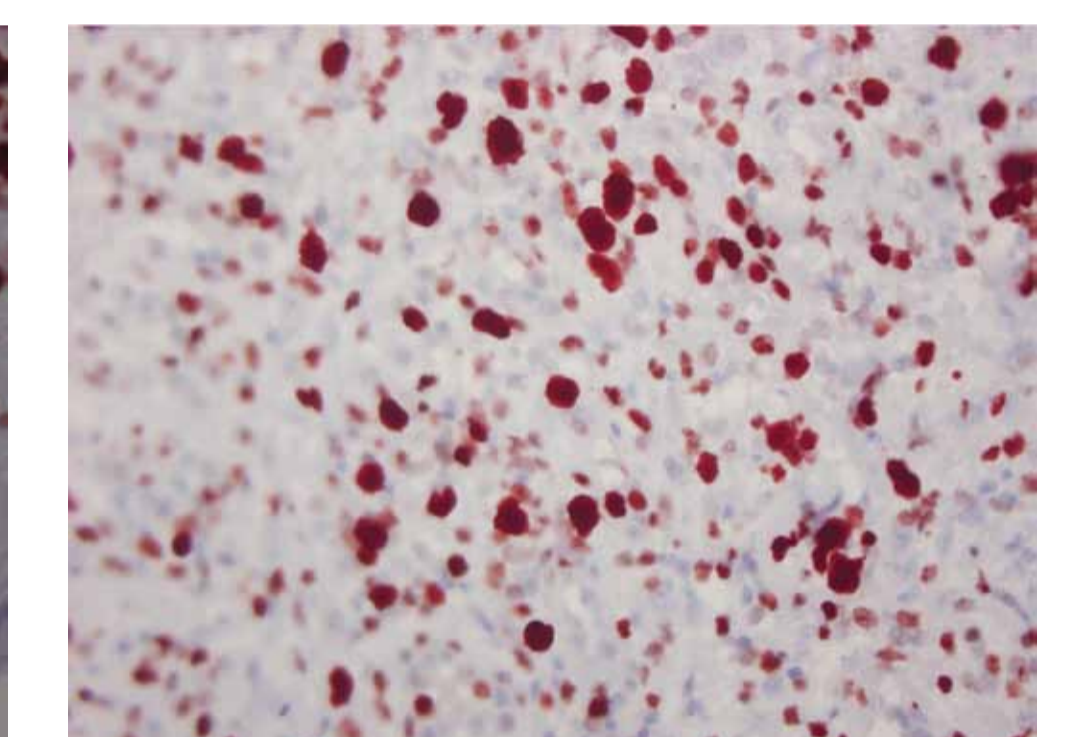


Ki67 Staining Pre-treatment



Ki67 Staining Post-treatment

Note the increased proliferative activity in the neoepidermis



Ki67 Staining of the granulation tissue post-treatment

Note the increased mitotic activity in the granulation tissue

DISCUSSION

Ultrasound has been known to have a stimulating affect on soft tissue healing including tendon, ligament and bone. Ultrasound has also been used as adjunctive therapy in treating lesions of the skin and skin related structures with varying results. Of late, low frequency, low intensity ultrasound therapy (LIUS) has found its way into the treatment regiment of chronic skin wounds in a variety of formulations. Most LIUS devices have the drawback of being both very bulky and very expensive, thereby limiting their use for very short periods of treatment.

Surface acoustic wave (SAW) has an added advantage in that it moves laterally across the surface of the wound. This enables the transfer of the acoustic energy along the whole wound surface in a continuous and consistent mode. The US diathermy patch is small, cost effective and allows for almost continuous application of US therapy enabling access to its benefits for a longer treatment period without the need for supervision or a treatment session by a clinician.

CONCLUSION

PainShield has a positive affect on both epithelialization of diabetic wounds, as well as in stimulating the precursors of dermal and epidermal growth. As such, it is a useful adjunct to wound care. Because of its size and low intensity it can be used in a much more effective way than standard ultrasound.

*- PainShield by Nanovibronix, Ltd.

